



PRESENTING CLINICAL SIGNS

History: Grade 2/6 murmur.

DATE

11/1/22

ECHOCARDIOGRAPHIC FINDINGS

2D, M-mode, and Doppler study.

PERFORMED BY:

Kelly Vazquez

INTERPRETED BY

Keith Blass, DVM,
MS, DACVIM
(Cardiology)

PATIENT

Mendez Amit

Left atrial size is normal. The mitral valve is normal. Left ventricular wall thickness is normal. Left ventricular internal dimensions are normal. Left ventricular systolic function is hyperdynamic. The aorta and aortic valve are normal. Right atrial and right ventricular dimensions are normal. The tricuspid valve appears normal, though very mild tricuspid regurgitation is present. The pulmonary artery and pulmonic valve appear normal, though trace pulmonic insufficiency is present. No shunting lesions are visualized. No pericardial effusion or cardiac masses are seen.

LA/Ao - 1.23
IVSd - 4.5 mm
LVPWd - 3.7 mm
LVIDd - 12.5 mm
LVIDs - 4.6 mm
FS - 63%
RA - 11.0 mm
LVOT - 1.02 m/s
RVOT - 0.85 m/s

ASSESSMENT/RECOMMENDATIONS

SPECIES

Feline

This examination demonstrates very mild regurgitation of blood across Mendez's mitral valve. The hemodynamic effects of the regurgitation also appear to be mild, as Mendez does not have secondary dilation of either of his right heart chambers. As such, Mendez's current risk for the development of right-sided congestive heart failure appears to be low.

BREED

DSH

No therapy is recommended at this stage of disease.

A recheck echocardiogram is recommended in 9-12 months to monitor for disease progression.

SEX

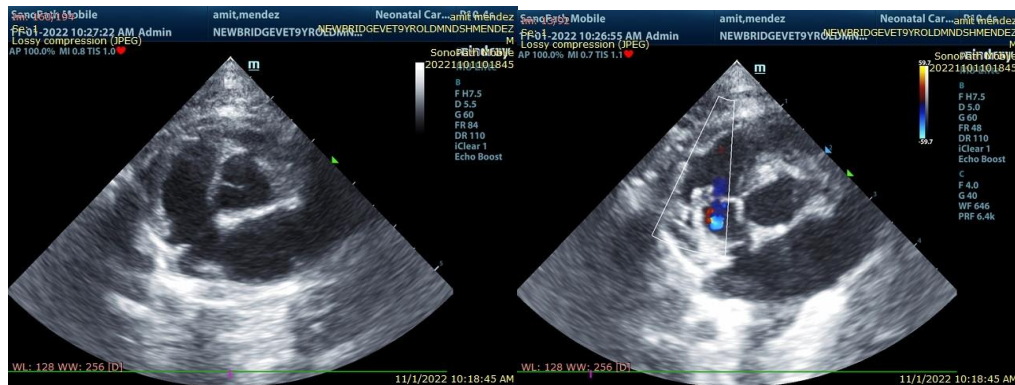
MN

AGE

9 y

WEIGHT

9.6 lb



HOSPITAL NAME

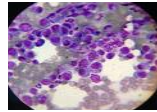
New Bridge VP

The information and recommendations provided are based on the images presented by the referring veterinarian. No evaluation can be communicated regarding pathology that was not visible in the image/video clips provided.

REFERRING VET

Dr. Glennon

Thank you for this referral. If the clinical or image interpretation does not parallel your findings or



if I can be of any further assistance please contact me.

DATE

11/1/22

Keith Blass, DVM, MS, DACVIM (Cardiology)

KeithBlass@gmail.com

631-804-5754

PERFORMED BY:

Kelly Vazquez

INTERPRETED BY

Keith Blass, DVM,

MS, DACVIM

(Cardiology)

PATIENT

Mendez Amit

SPECIES

Feline

BREED

DSH

SEX

MN

AGE

9 y

WEIGHT

9.6 lb

HOSPITAL NAME

New Bridge VP

REFERRING VET

Dr. Glennon